

**Male in his 70's**

**Target: Lt SFA**

**Points: CTO**

**Rutherford: 3      Wound: None**

**ABI: 0.58**

**Risk factors: HT, DM, DL, past smoking**

**Present illness:**

**2023/3~ Bilateral intermittent claudication**

**Prior EVT:**

**2024/3/21 Rt SFA-PopA IN .PACT 5x200+5x200**

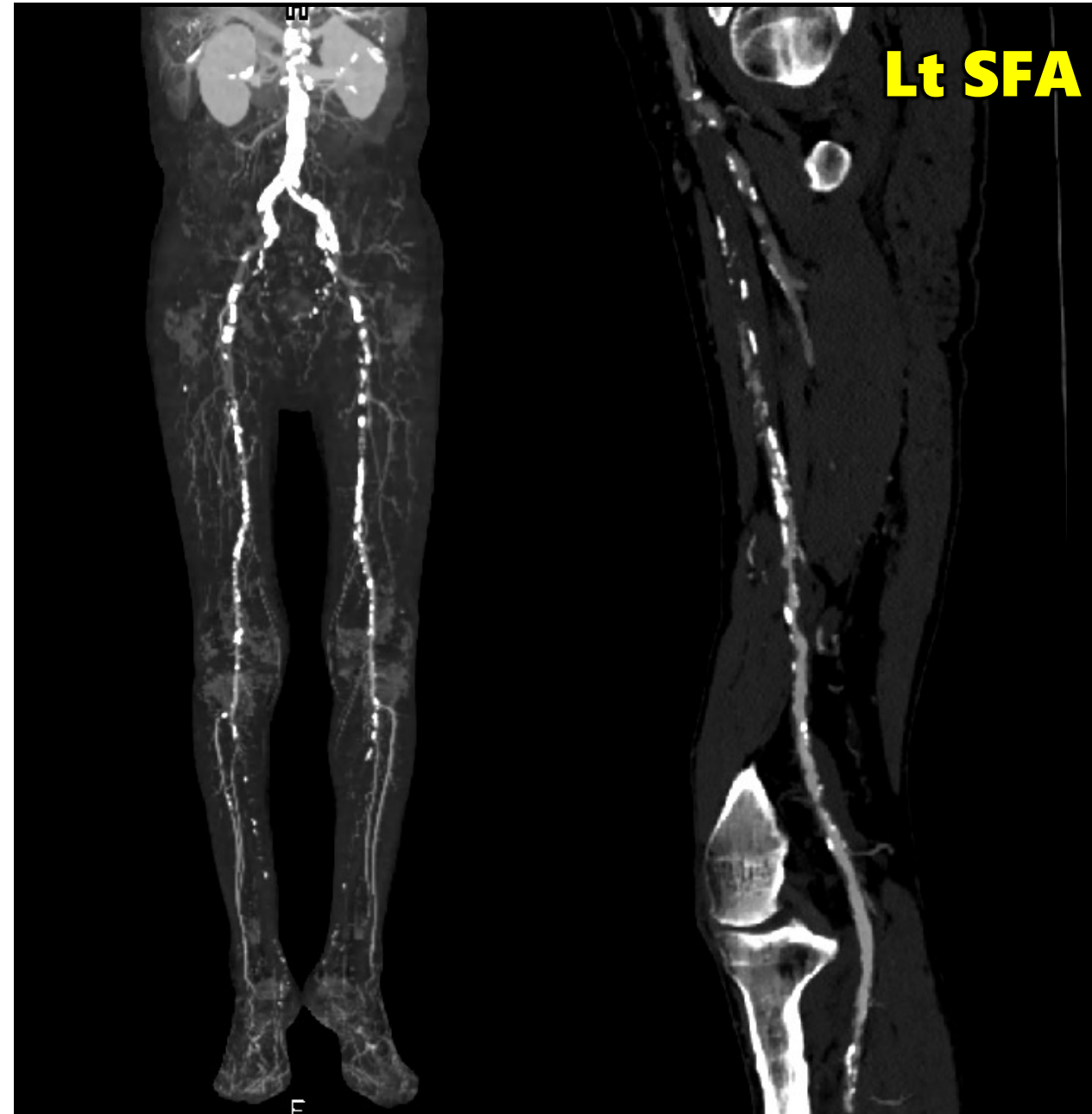**Prior PCI or CABG: None**

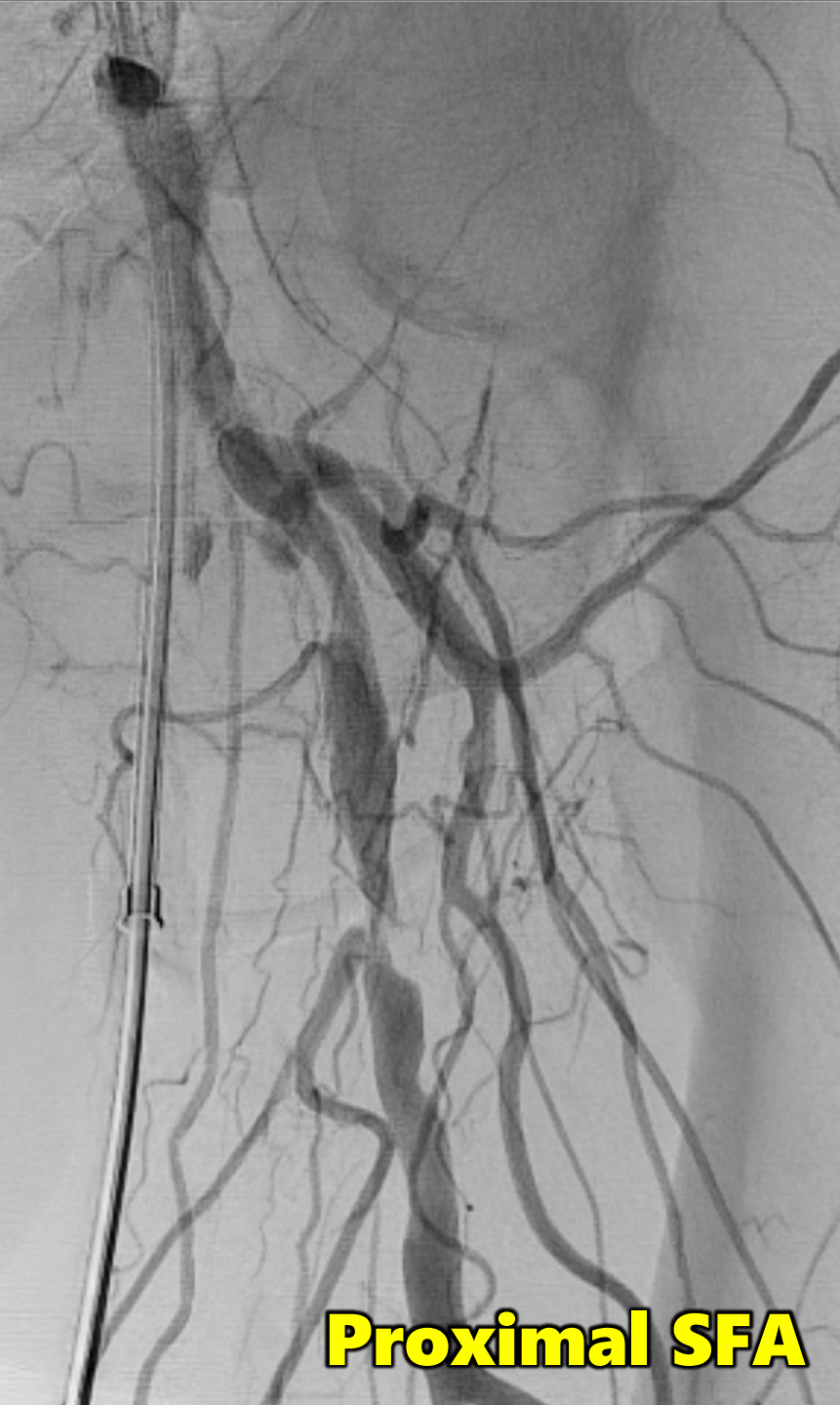**Prior CVD: None**

**Drug: Clopidogrel, Statin**

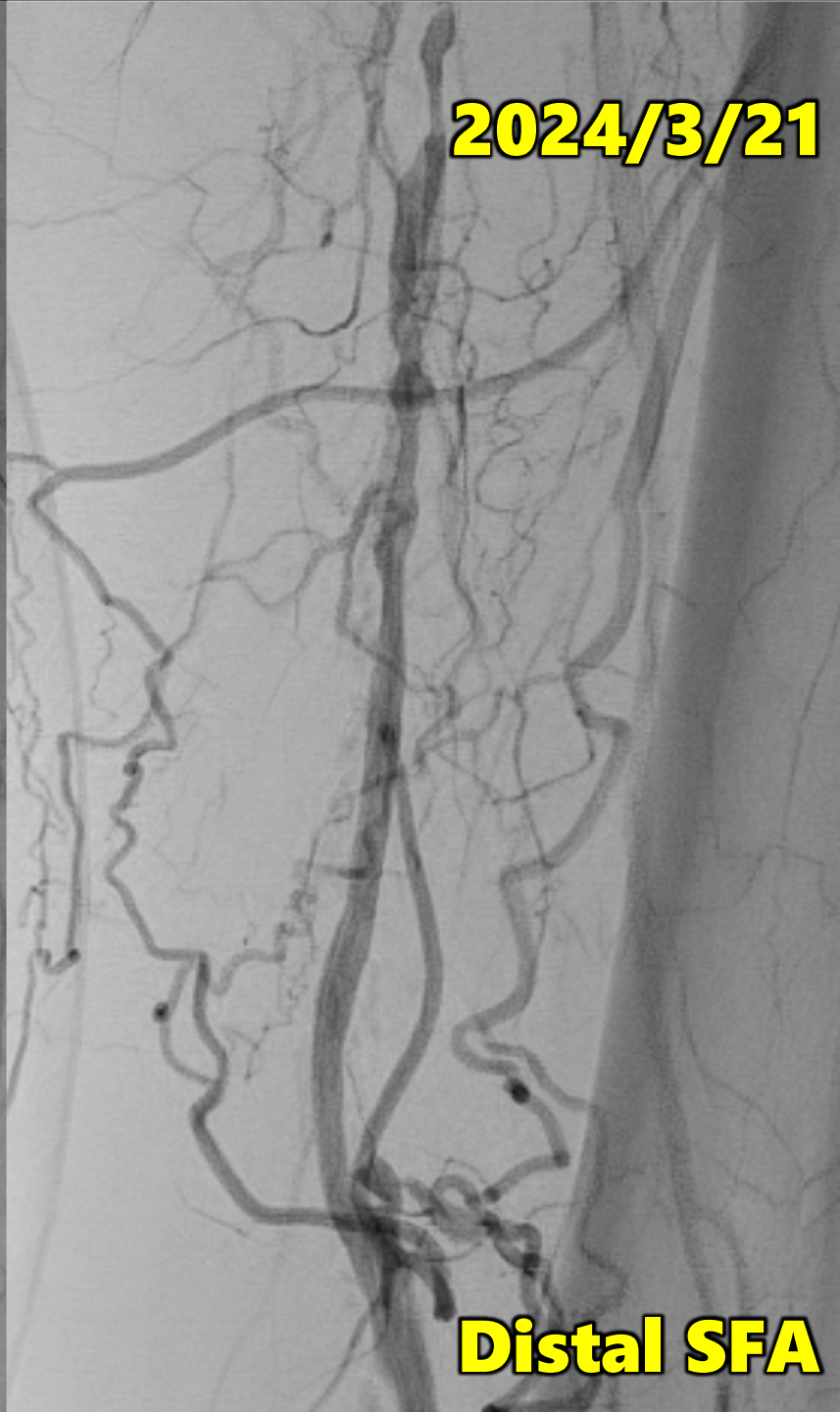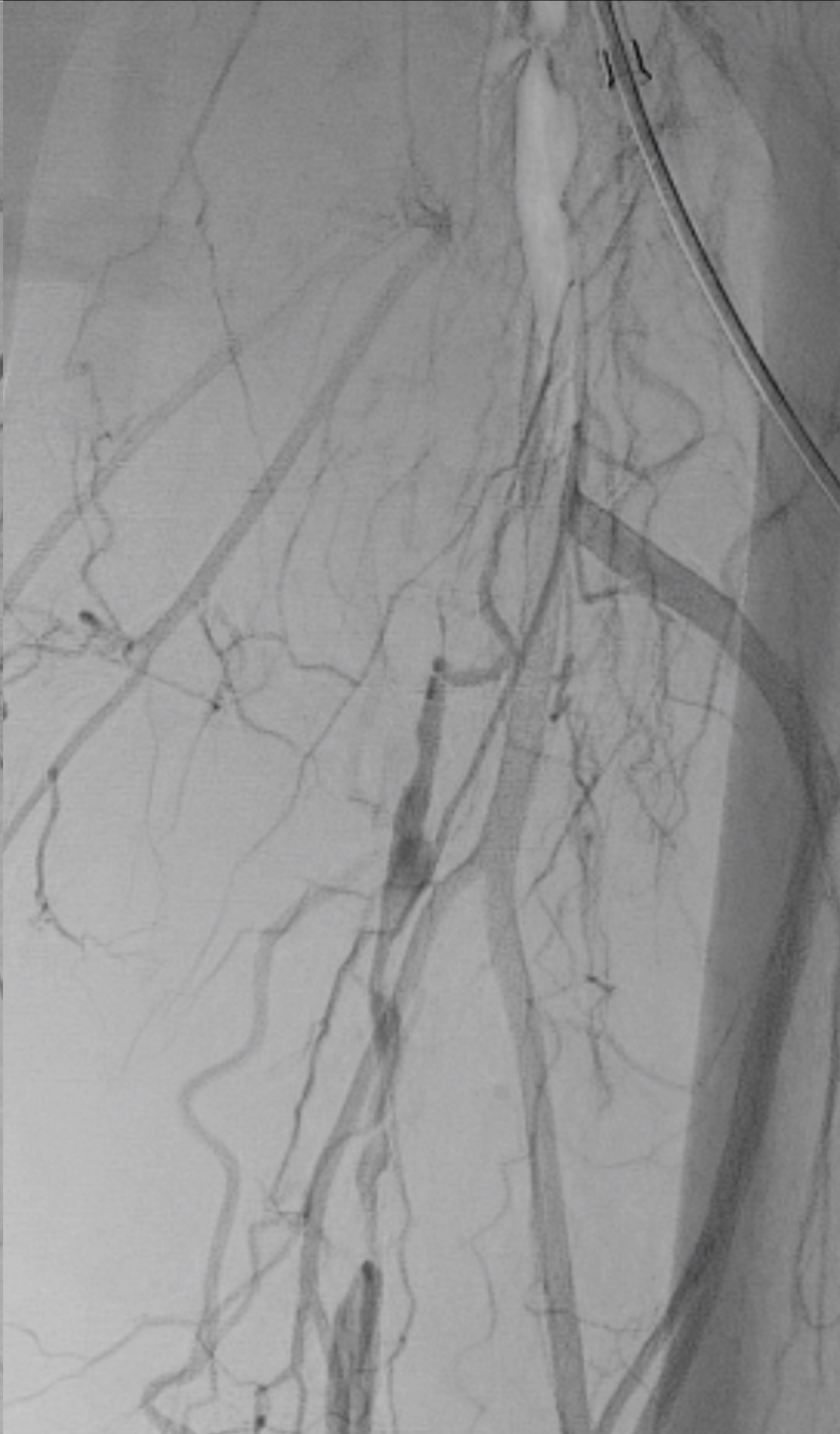
**Inspection:**

**Cr 0.74, eGFR 79.0, A1c 6.6 %, EF 69 %, asynergy (-), Afib (-)**





**Proximal SFA**



**Distal SFA**

**Male in his 80's**

**Target: Lt SFA**

**Points: CTO**

**Rutherford: 3      Wound: None**

**ABI: 0.61**

**Risk factors: HT, DL, DM, CKD, past smoking**

**Present illness:**

**2023/11~ Bilateral intermittent claudication**

**Prior EVT:**

**Rt SFA, LtEIA post stenting(Detail unknown)**

**2024/3/21**

**Rt EIA EPIC 8x40**

**Rt SFAISR-PopP1 IN.PACT 5x200+4x150**

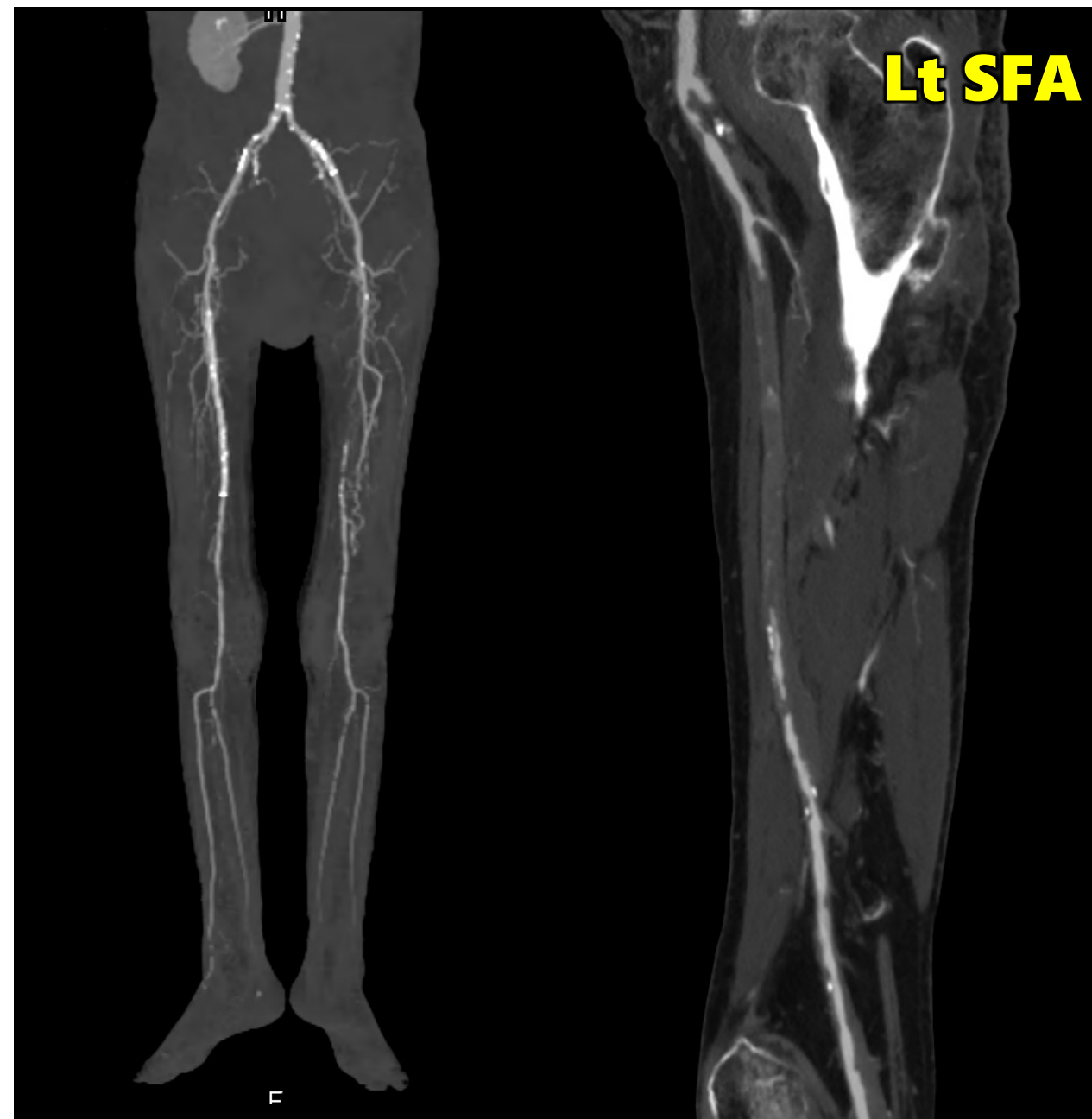
**Prior PCI: (+)**

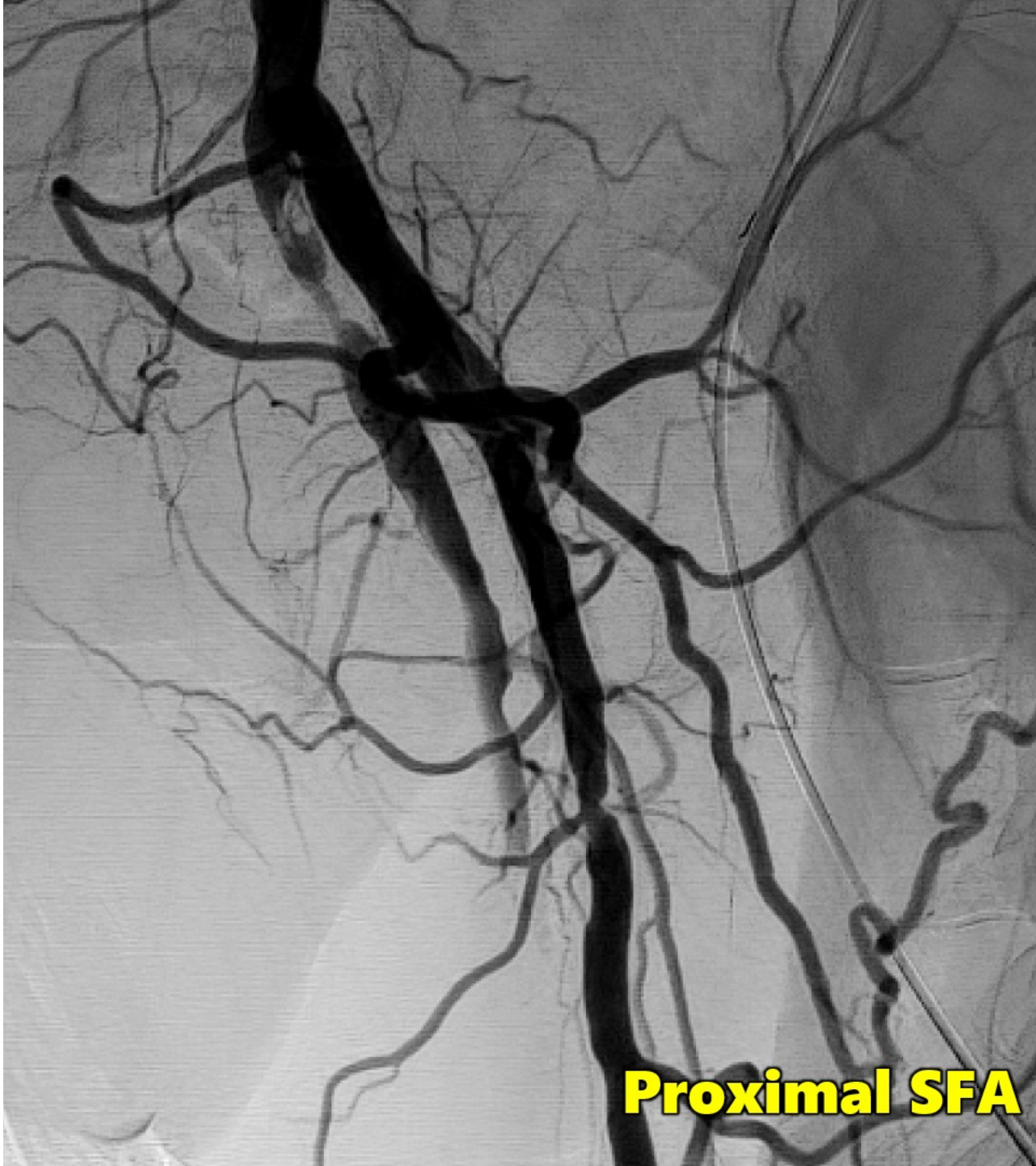
**Prior CVD: (+)**

**Drug: ASA, Clopidogrel, DOAC, Statin**

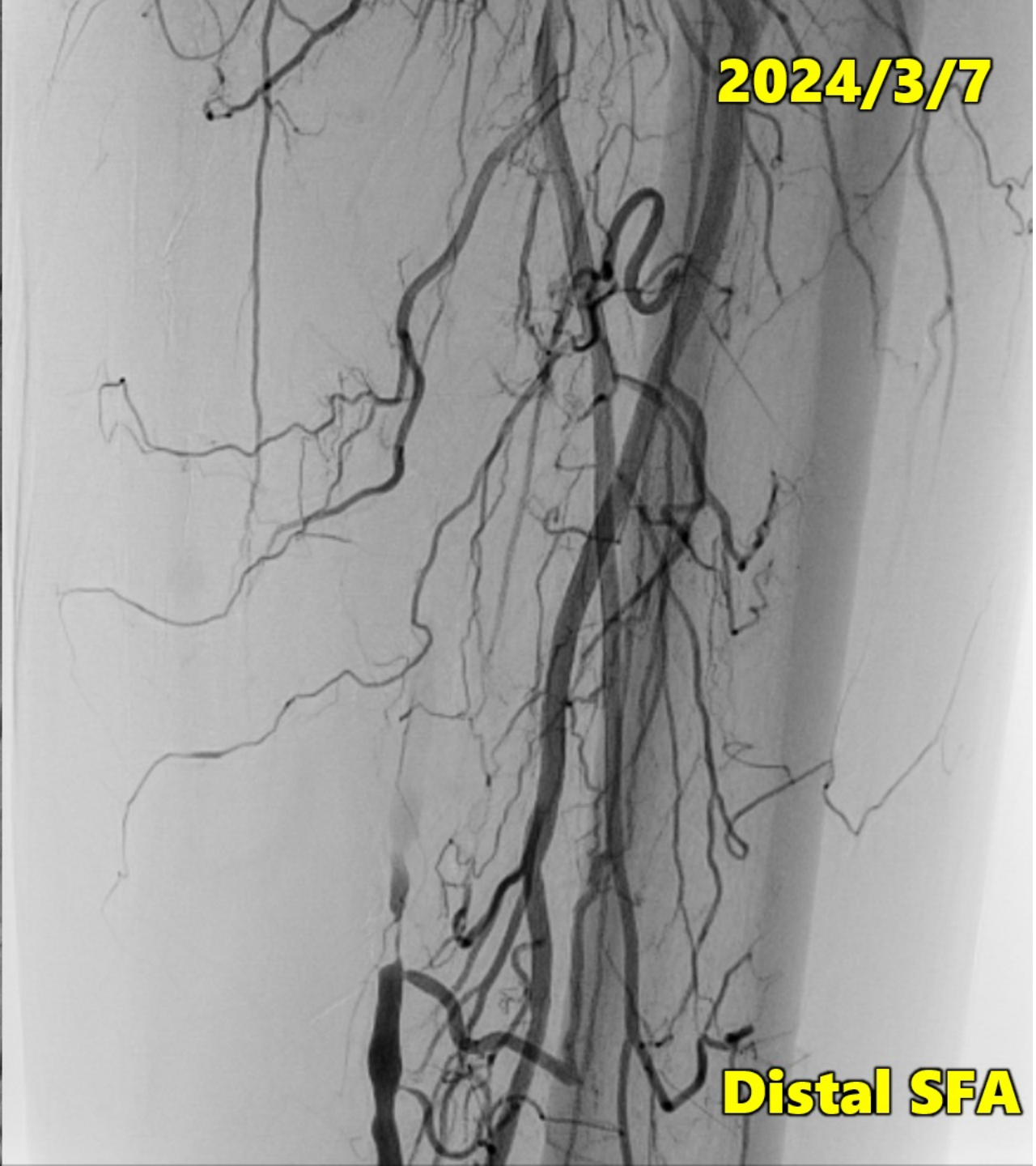**Inspection:**

**Cr 0.92, eGFR 58.6, A1c 5.3 %, EF 60 %, asynergy (-), Afib (+)**





**Proximal SFA**



**2024/3/7**

**Distal SFA**

**Male in his 80's**

**Target: Rt EIA, SFA**

**Points: EIA-CTO, SFA stenosis**

**Rutherford: 4      Wound: None**

**ABI: 0.68**

**Risk factors: HD, DL**

**Present illness:**

**2023/3~ Right rest pain**

**Prior EVT: None**

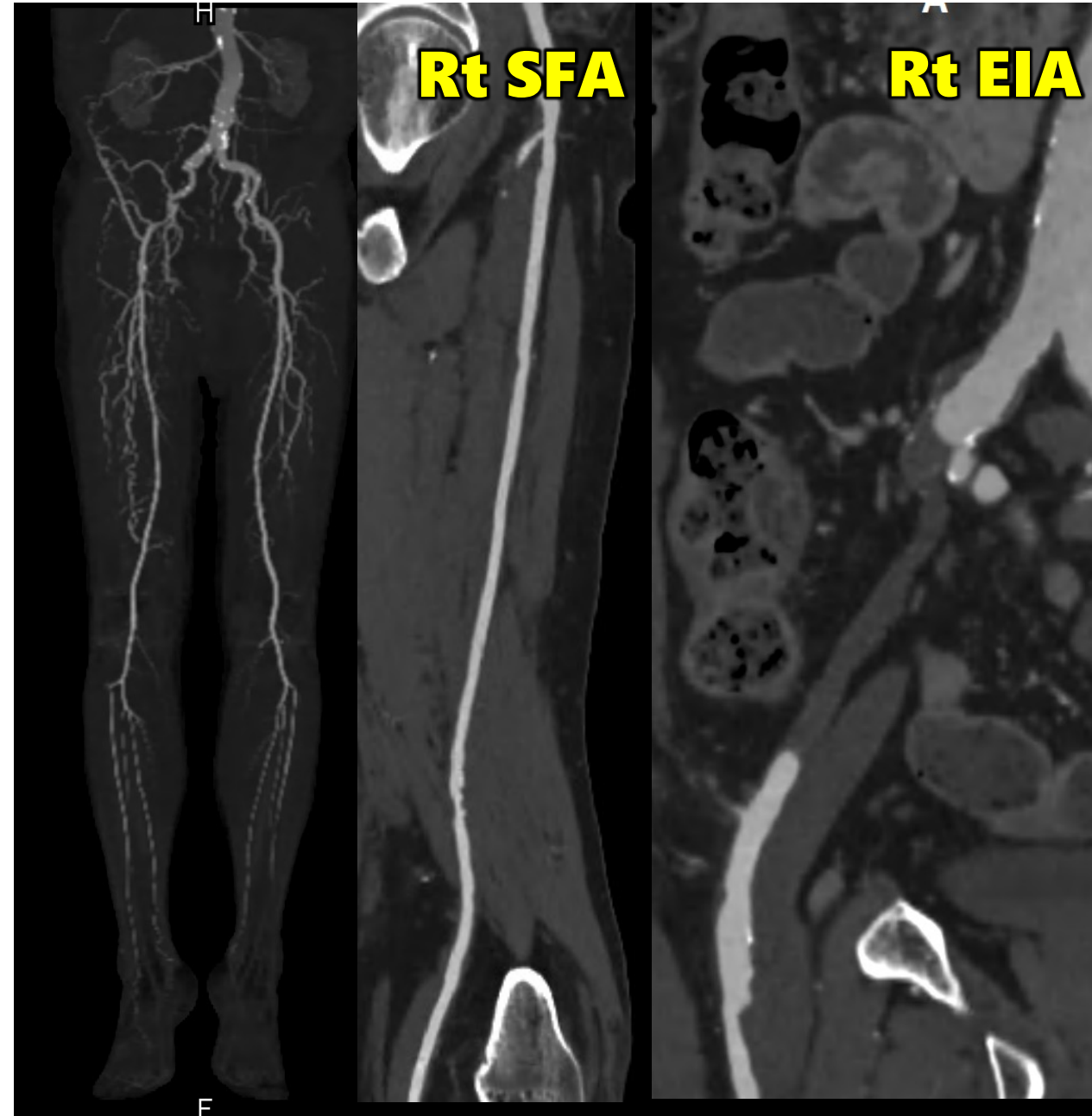
**Prior PCI or CABG: None**

**Prior CVD: None**

**Drug: ASA, Statin**

**Inspection:**

**Cr 5.38, eGFR 8.8, A1c 5.0 %, EF 56 %, asynergy (-), Afib (+)**



**Female in her 80's**

**Target: Lt BKA**

**Points: CTO**

**Rutherford: 4      Wound: None**

**ABI: 0.73**

**Risk factors: HT, DL, CKD, CVD, postTAVI**

**Present illness:**

**2023/11~ Rt 1<sup>st</sup> ulcer/Lt rest pain**

**Prior EVT:**

**2024/3/7 Rt PA 2.0BC, Rt ATATO 2.5BC**

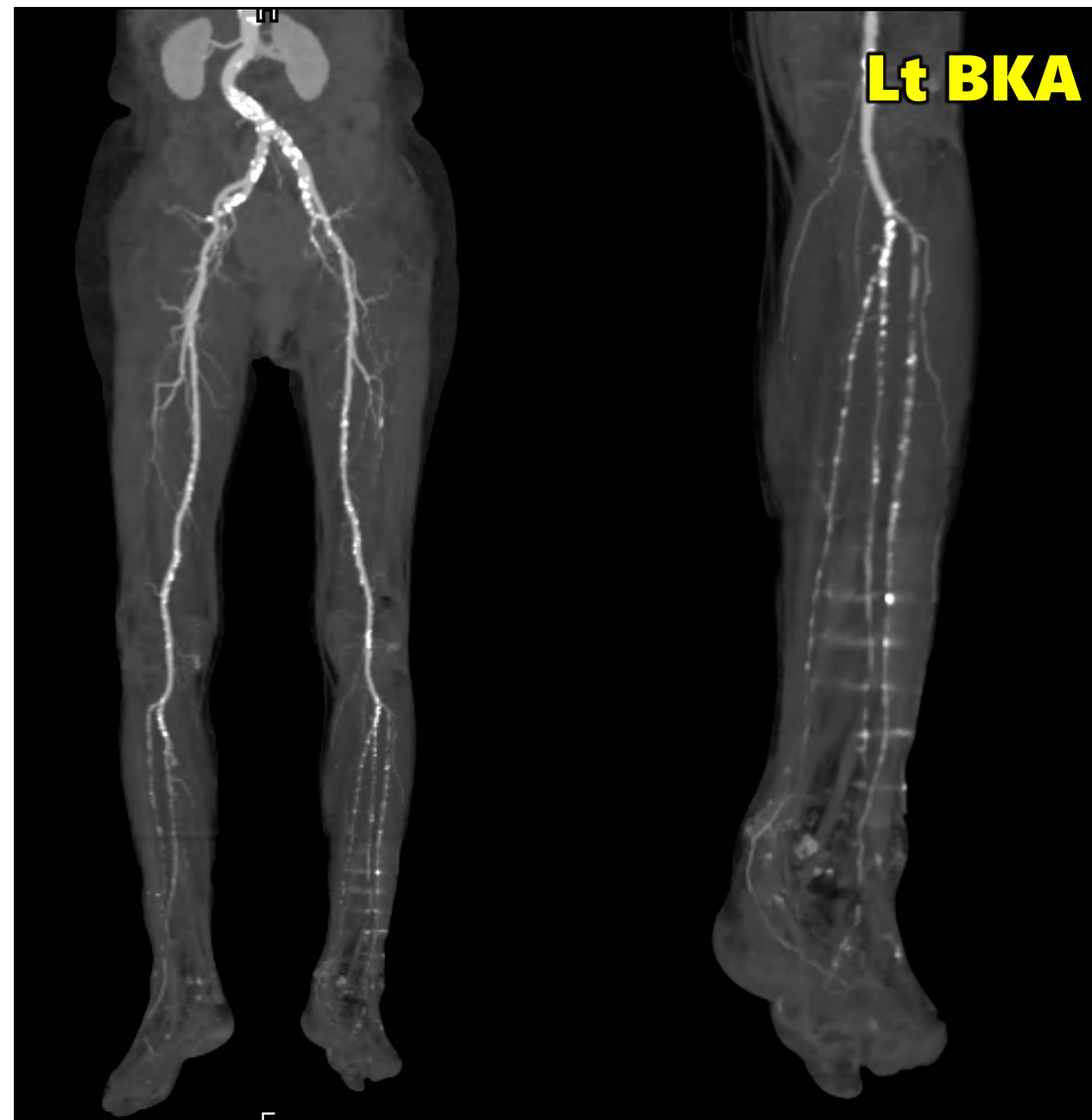**Prior PCI or CABG: None**

**Prior CVD: (+)**

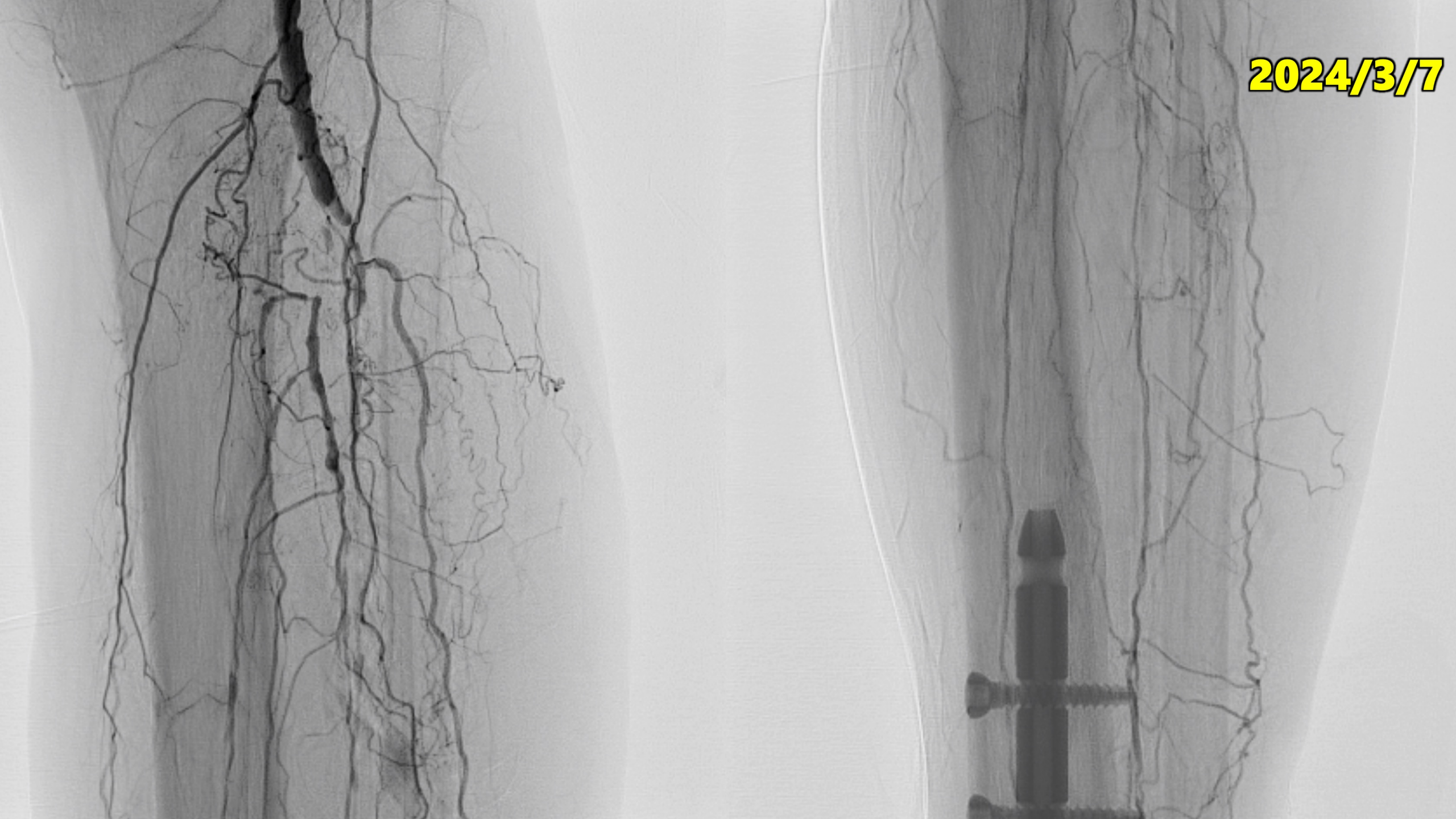
**Drug: ASA, Clopidogrel, Statin**

**Inspection:**

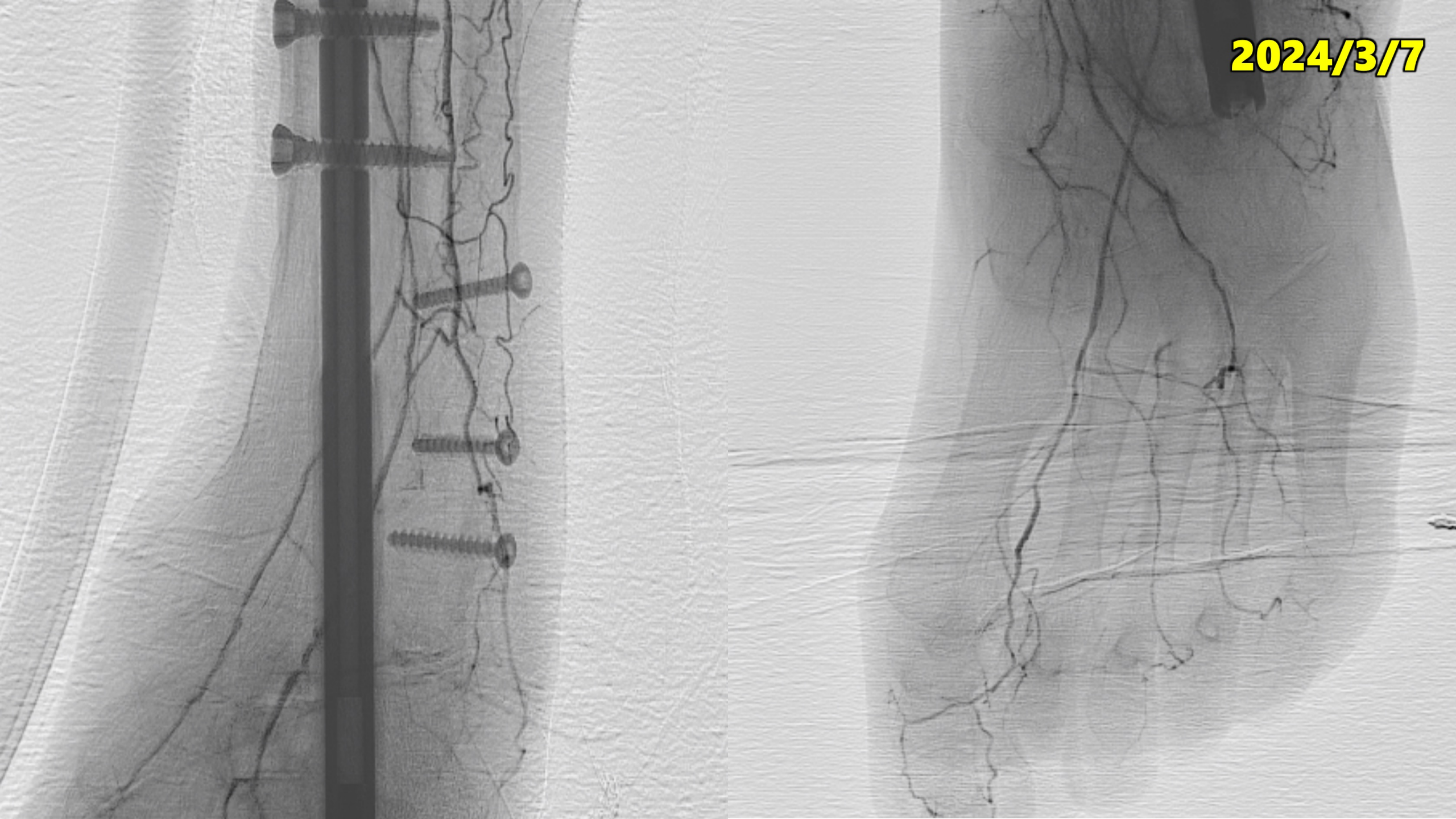**Cr 0.85, eGFR 47.7, A1c 5.0 %, EF 69 %, asynergy (-), Afib (-)**



**2024/3/7**



**2024/3/7**





**Male in his 70's**

**Target: Ao, RtEIA, SFA**

**Points: Ao stenosis, EIA stenosis, SFA-CTO**

**Rutherford: 4      Wound: None**

**ABI: 0.53**

**Risk factors: CVD, Smoking**

**Present illness:**

**2023/3 ~ Right intermittent claudication**

**Prior EVT: None**

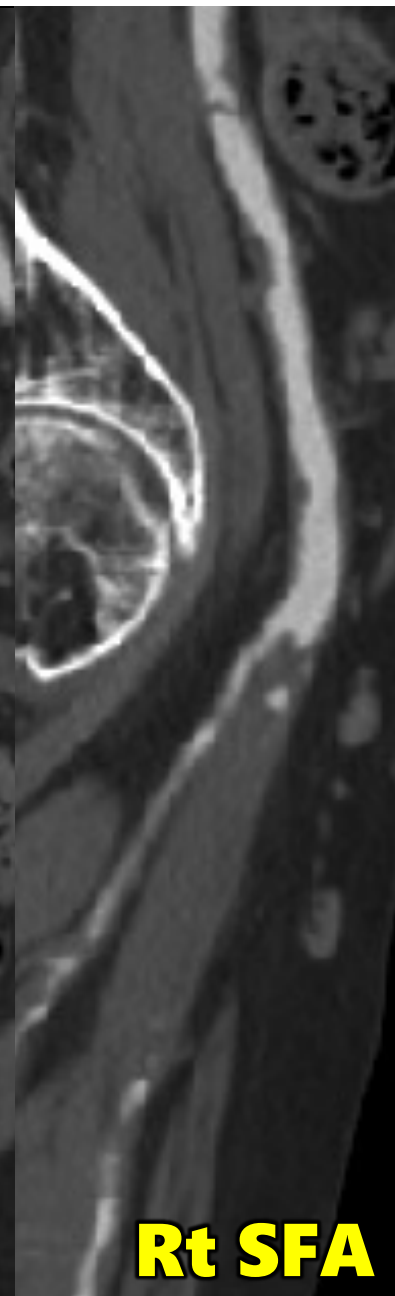
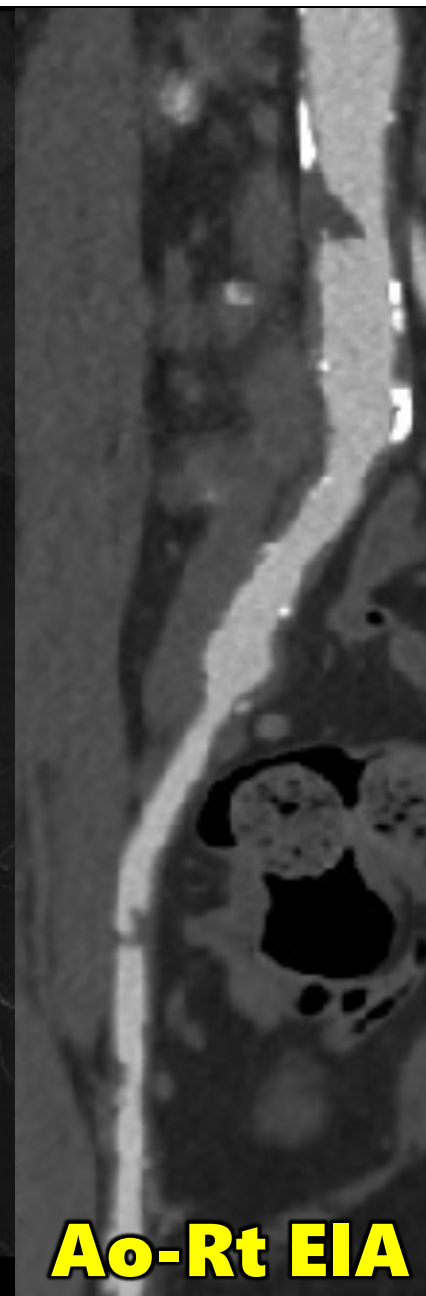
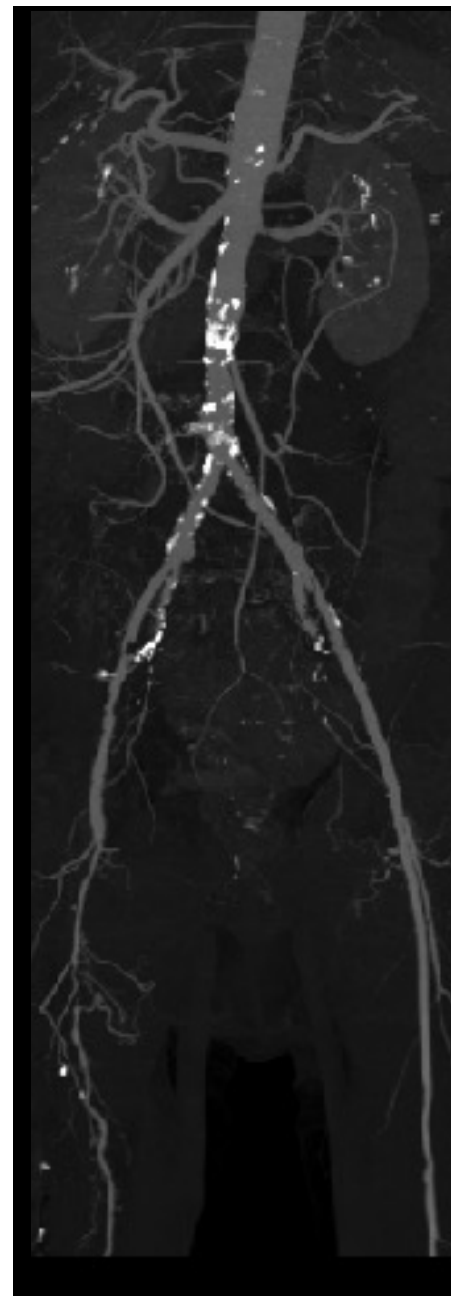
**Prior PCI or CABG: (-)**

**Prior CVD: (+)**

**Drug: ASA, Clopidogrel**

**Inspection:**

**Cr 0.43, eGFR 144, A1c 5.3 %, EF 76 %, asynergy (-), Afib (-)**



**Ao-Rt EIA**

**Rt SFA**

**Female in her 50's**

**Target: Lt SFA**

**Points: CTO**

**Rutherford: 3      Wound: None**

**ABI: 0.66**

**Risk factors: DM, DL, CAD**

**Present illness:**

**2023/3 ~ Left intermittent claudication**

**Prior EVT:**

**2019/9/19 RtPA/PTA 2.5BC**

**Prior PCI : (+)**

**Prior CVD: (+)**

**Drug: ASA, Clopidogrel**

**Inspection:**

**Cr 0.43, eGFR 144, A1c 5.3 %, EF 76 %, asynergy (-), Afib (-)**

**Lt SFA**

